



Comparative outcomes of abdominal, laparoscopic, and vaginal sacral colpopexy: A national analysis of apical suspension procedures (2014-2022)

Abdominal, laparoskopik ve vajinal sakral kolpopeksinin karşılaştırmalı sonuçları: Apikal süspansiyon prosedürlerinin ulusal analizi (2014-2022)

© Smit Bharat Solanki¹, © Apurva B. Pancholy², © Vishal Pancholy³

¹Dr. H. L. Trivedi Institute of Transplantation Sciences (IKDRC-ITS), Institute of Kidney Diseases and Research Center, Department of Obstetrics and Gynaecology, Ahmedabad, India

²The University of Texas Health Science Center at Houston (UTHealth Houston), McGovern Medical School,) Division of Urogynecology, Texas, USA

³Texas A&M University, College Station, Texas, USA

Abstract

Objective: Sacral colpopexy is a well-established procedure for apical suspension, but the relative outcomes of abdominal, laparoscopic, and vaginal approaches remain debated. This study compared perioperative outcomes across these surgical routes using a national database and evaluated trends in robotic assistance.

Materials and Methods: We analyzed sacral colpopexy cases from the American College of Surgeons National Surgical Quality Improvement Program between 2014 and 2022. Patient demographics, complication rates, and surgical outcomes were compared among abdominal, laparoscopic, and vaginal procedures. Relative risks (RR) were adjusted for confounders. The utilization of robotic systems in laparoscopic procedures was examined.

Results: Among 61,524 cases, 3,497 (5.7%) were abdominal, 22,752 (37.0%) laparoscopic, and 35,275 (57.3%) vaginal. Vaginal procedures were more common in older patients, while laparoscopic approaches predominated among younger and higher-body mass index patients. Non-Hispanic White patients most often underwent vaginal surgery (60.5%), whereas African American patients most frequently underwent laparoscopic procedures (6.4%). Laparoscopic sacral colpopexy had the lowest complication rate (7.8%), with fewer superficial surgical site infections, transfusions, readmissions, and reoperations. Adjusted analysis showed a lower risk with laparoscopic surgery compared with abdominal surgery [RR: 0.75, 95% confidence interval (CI): 0.67-0.85]. Vaginal surgery showed no significant difference compared with abdominal surgery (RR: 1.09, 95% CI: 0.97-1.21). Robotic assistance increased markedly, comprising 73.5% of laparoscopic procedures in 2022.

Conclusion: Laparoscopic sacral colpopexy, particularly with robotic assistance, is associated with fewer perioperative complications compared with abdominal and vaginal approaches. These findings support minimally invasive techniques as preferred approaches for apical suspension, and further research is needed on long-term outcomes and cost-effectiveness.

Keywords: Sacral colpopexy, laparoscopic surgery, robotic surgery, apical suspension, pelvic organ prolapse, surgical outcomes

PRECIS: In an analysis of 61,524 national cases, we found that laparoscopic sacral colpopexy—especially robotic-assisted—had the lowest perioperative complication rate compared with abdominal and vaginal approaches.

Corresponding Author/Sorumlu Yazar: Smit Bharat Solanki, Prof. MD,

Department of Obstetrics and Gynaecology, Institute of Kidney Diseases and Research Center, Dr. H. L. Trivedi Institute of Transplantation Sciences (IKDRC-ITS), Ahmedabad, India

E-mail: drsmitbharat@gmail.com ORCID ID: orcid.org/0009-0006-6475-7223

Received/Geliş Tarihi: 14.11.2025 Accepted/Kabul Tarihi: 06.01.2026 Epub: 29.01.2026 Publication Date/Yayınlanma Tarihi: 04.06.2026

Cite this article as: Solanki SB, Pancholy BA, Pancholy V. Comparative outcomes of abdominal, laparoscopic, and vaginal sacral colpopexy: a national analysis of apical suspension procedures (2014-2022). Turk J Obstet Gynecol. 2026;23(2):153-59



Öz

Amaç: Sakral kolpopeksi, apikal süspansiyon için iyi bilinen bir prosedürdür, ancak abdominal, laparoskopik ve vajinal yaklaşımların göreceli sonuçları hala tartışılmaktadır. Bu çalışma, ulusal bir veri tabanı kullanarak bu cerrahi yollar arasında perioperatif sonuçları karşılaştırdı ve robotik yardımdaki eğilimleri değerlendirdi.

Gereç ve Yöntemler: 2014 ve 2022 yılları arasında Amerikan Cerrahlar Koleji Ulusal Cerrahi Kalite İyileştirme Programı'ndan sakral kolpopeksi olgularını analiz ettik. Hasta demografik özellikleri, komplikasyon oranları ve cerrahi sonuçlar abdominal, laparoskopik ve vajinal prosedürler arasında karşılaştırıldı. Göreceli riskler (RR) karıştırıcı faktörlere göre ayarlandı. Laparoskopik prosedürlerde robotik sistemlerin kullanımı incelendi.

Bulgular: 61.524 olgu arasında 3.497'si (%5,7) abdominal, 22.752'si (%37,0) laparoskopik ve 35.275'i (%57,3) vajinaldi. Vajinal işlemler daha yaşlı hastalarda daha yaygınken, laparoskopik yaklaşımlar daha genç ve yüksek vücut kitle indeksli hastalarda baskınlık gösterdi. Hispanik olmayan beyaz hastalar en sık vajinal cerrahi %60,5 geçirirken, Afrika kökenli Amerikalı hastalar en sık laparoskopik işlemlere %6,4 tabi tutuldu. Laparoskopik sakral kolpopeksi en düşük komplikasyon oranına (%7,8) sahipti ve daha az yüzeysel cerrahi bölge enfeksiyonu, kan transfüzyonu, yeniden hastaneye yatış ve yeniden ameliyat gerektirdi. Ayarlanmış analiz, laparoskopik cerrahinin karın cerrahisine kıyasla daha düşük risk taşıdığını gösterdi [RR: 0,75, %95 güven aralığı (GA): 0,67-0,85]. Vajinal cerrahi, karın cerrahisine kıyasla anlamlı bir fark göstermedi (RR: 1,09, %95 GA: 0,97-1,21). Robotik destek belirgin şekilde artarak 2022 yılında laparoskopik işlemlerin %73,5'ini oluşturmuştur.

Sonuç: Laparoskopik sakral kolpopeksi, özellikle robotik destekle birlikte, abdominal ve vajinal yaklaşımlara kıyasla daha az perioperatif komplikasyonla ilişkilidir. Bu bulgular, apikal süspansiyon için tercih edilen yaklaşımlar olarak minimal invaziv teknikleri desteklemektedir ve uzun vadeli sonuçlar ve maliyet etkinliği konusunda daha fazla araştırmaya ihtiyaç vardır.

Anahtar Kelimeler: Sakral kolpopeksi, laparoskopik cerrahi, robotik cerrahi, apikal süspansiyon, pelvik organ prolapsusu, cerrahi sonuçlar

Introduction

Pelvic organ prolapse (POP) is a common condition that significantly impairs quality of life by causing pelvic pressure, urinary incontinence, bowel dysfunction, and sexual difficulties. Apical suspension surgery is central to the management of advanced POP, as restoration of the vaginal apex is critical for durable pelvic support and prevention of recurrent prolapse. Sacral colpopexy, most commonly performed using mesh, is widely considered the gold-standard procedure for apical suspension because of its robust long-term outcomes. Sacral colpopexy can be performed through abdominal, laparoscopic, or vaginal approaches. Abdominal sacrocolpopexy, historically the standard, offers durable anatomical correction, but is associated with longer recovery times and higher perioperative morbidity. Minimally invasive approaches, including laparoscopic and robotic-assisted sacral colpopexy, have been increasingly adopted given their advantages of reduced blood loss, shorter hospital stays, and faster return to normal activities. The introduction of robotic technology has further advanced minimally invasive techniques by providing enhanced visualization, improved dexterity, and ergonomic benefits. Nevertheless, concerns remain regarding costs, learning curves, and long-term outcomes, particularly in relation to mesh-related complications. Vaginal approaches, such as uterosacral ligament suspension and sacrospinous ligament fixation, remain important alternatives, especially for older patients or those unfit for abdominal surgery. While these techniques avoid abdominal entry and can be performed under regional anesthesia, they may be associated with higher recurrence rates and different complication profiles compared to abdominal and laparoscopic approaches. Despite the variety of surgical options, contemporary comparative data on demographic trends, complication risks, and outcomes by surgical route remain limited. Furthermore, the extent to which robotic

assistance has transformed laparoscopic sacral colpopexy in routine clinical practice is not fully established. The objective of this study was to compare patient characteristics and perioperative outcomes among patients undergoing abdominal, laparoscopic, and vaginal sacral colpopexy using a large national surgical database and to evaluate recent trends in robotic utilization.

Materials and Methods

Study Objectives

The objective of this study was to analyze demographic trends, perioperative complications, and the impact of robotic assistance on sacral colpopexy procedures performed between 2014 and 2022. Comparisons were made among abdominal, laparoscopic, and vaginal approaches to identify the safest and most effective strategies for apical suspension in women with POP.

Data Source and Study Population

Data were obtained from the American College of Surgeons National Surgical Quality Improvement Program (ACS-NSQIP) database for the years 2014-2022. Patients who underwent sacral colpopexy were identified using the following Current Procedural Terminology (CPT) codes:

- Abdominal open: 57270, 57280
- Laparoscopic: 57425
- Vaginal: 57282, 57283, 57268

Exclusion criteria included patients without colpopexy (n=4.890.409), patients with more than one route of colpopexy (n=496), patients with a cancer diagnosis (n=1.144), and patients with missing operative time (n=3). After applying exclusions, 61,524 cases were included in the final analysis. The abdominal open group was used as the reference category.

Outcomes

The primary outcome was composite perioperative morbidity, defined as the occurrence of one or more of the following complications within 30 days:

- Surgical site infection (superficial, deep, organ/space, or wound dehiscence)
- Pulmonary complications (pneumonia, unplanned intubation, prolonged ventilation)
- Cardiac complications (cardiac arrest requiring cardiopulmonary resuscitation, myocardial infarction)
- Renal complications (acute renal insufficiency, progressive renal failure)
- Sepsis (sepsis or septic shock)
- Thromboembolic events (pulmonary embolism, deep vein thrombosis, cerebrovascular accident/stroke with neurologic deficit)
- Urinary tract infection
- Postoperative blood transfusion
- Prolonged hospital stay (defined as >2 days)

Statistical Analysis

Descriptive statistics were used to summarize demographic and clinical characteristics. Continuous variables were analyzed using the Student's t-test for normally distributed data and the Wilcoxon rank-sum test for skewed distributions. Categorical variables were compared using chi-square or Fisher's exact test, as appropriate. To assess the association between surgical route and composite morbidity, multivariable logistic regression was performed, adjusting for age, race, American Society of Anesthesiologists (ASA) classification, smoking status, and operative time. Results were expressed as adjusted odds ratios with 95% confidence intervals (CIs). A two-sided p-value <0.05 or a 95% CI not crossing 1.0 was considered statistically significant.

Ethics Approval

As this study used de-identified data from the NSQIP database, institutional review board approval and informed consent were not required.

Results

A total of 61,524 women who underwent sacral colpopexy between 2014 and 2022 were included. Of these, 3,497 (5.7%) underwent an abdominal approach, 22,752 (37.0%) underwent a laparoscopic approach, and 35,275 (57.3%) underwent a vaginal approach.

Patient Demographics

Patient demographics differed significantly across groups (Table 1). Women undergoing vaginal colpopexy were more likely to be aged ≥ 75 years (13.5%) than those undergoing laparoscopic (7.9%) and abdominal (10.0%) cases ($p < 0.001$). Conversely, younger women (<45 years) were more frequently represented in the laparoscopic group (15.2%, $p < 0.001$). Non-Hispanic White patients predominated across all approaches, although the proportion was lowest in the laparoscopic group (54.3%) compared with the abdominal (58.1%) and vaginal (60.5%) groups ($p < 0.001$). Obesity (body mass index ≥ 30) was most common in the vaginal cohort (35.3%; $p < 0.001$). Concomitant hysterectomy was most frequently performed laparoscopically (73.6%, $p < 0.001$).

Operative Characteristics

Median operative time and length of hospitalization varied significantly by approach (Table 2). Prolonged operative time (>200 minutes) occurred most frequently in laparoscopic (38.1%) and abdominal (37.7%) cases, compared with vaginal cases (14.9%) ($p < 0.001$). The abdominal approach was overwhelmingly inpatient (81.2%), whereas the laparoscopic (81.3%) and vaginal (69.2%) approaches were more commonly outpatient. Median length of stay was longest after abdominal procedures [median 2 days, interquartile range (IQR) 1-3] compared with laparoscopic and vaginal procedures (both median 1 day, IQR 0-2; $p < 0.001$).

Trends over Time

Utilization patterns shifted markedly over the study period (Figure 1). Laparoscopic and vaginal approaches have increasingly supplanted abdominal sacrocolpopexy. Within the laparoscopic group, adoption of robotic assistance rose

Table 1. Baseline characteristics of patients undergoing sacral colpopexy, 2014-2022 (n=61,524)

Characteristic	Abdominal (n=3,497)	Laparoscopic (n=22,752)	Vaginal (n=35,275)	p-value
Age ≥ 75 years	10.0%	7.9%	13.5%	<0.001
Age <45 years	9.8%	15.2%	6.3%	<0.001
Race: Non-hispanic white	58.1%	54.3%	60.5%	<0.001
Race: Non-hispanic African American	5.5%	6.4%	4.1%	<0.001
Race: Hispanic	8.4%	7.9%	8.2%	0.09
BMI ≥ 30	33.2%	33.8%	35.3%	<0.001
BMI <30	66.8%	66.2%	64.2%	<0.001
Concomitant hysterectomy	59.2%	73.6%	64.6%	<0.001

steadily from 2014 to 2022, with nearly three-quarters of laparoscopic cases being robot-assisted by 2022 (Figure 2).

Perioperative Complications

Overall composite morbidity differed significantly across groups (Table 3). Abdominal sacrocolpopexy was associated with the highest complication rate (13.1%), followed by vaginal colpopexy (10.5%) and laparoscopic colpopexy (7.8%) (p<0.001). Abdominal procedures carried the greatest risks of superficial surgical site infection (2.6%), transfusion (4.7%), and readmission (4.7%). Laparoscopic colpopexy consistently demonstrated the lowest incidence of these events. In multivariable analysis, adjusting for age, race, ASA class, smoking, and operative time, laparoscopic colpopexy was associated with a significantly lower risk of composite morbidity compared with abdominal procedures (adjusted RR: 0.75, 95% CI: 0.67-0.85, p<0.001) (Table 4). Vaginal colpopexy demonstrated a slightly higher, but not statistically significant, risk relative to abdominal surgery (adjusted RR: 1.09, 95% CI: 0.97-1.21, p=0.12).

Graphical Comparison

Bar graph analysis (Figure 3) highlights the superior safety profile of laparoscopic procedures relative to abdominal and

vaginal approaches, with consistently lower complication rates across measured outcomes.

Discussion

This study provides one of the largest contemporary analyses of apical suspension procedures in the United States, utilizing the NSQIP database from 2014-2022. By examining 61,524 patients, we identified notable demographic and outcome trends among patients undergoing abdominal, laparoscopic, and vaginal sacral colpopexy. Our results demonstrate a progressive decline in the use of open abdominal sacral colpopexy, a steady rise in minimally invasive approaches—particularly with robotic assistance—and a stable, though less frequent, role for vaginal suspension. Furthermore, we observed significantly lower composite perioperative morbidity with laparoscopic colpopexy with abdominal colpopexy; vaginal procedures demonstrated an intermediate risk profile. Although NSQIP categorizes vaginal apical suspension procedures under colpopexy-related CPT codes, true sacral colpopexy is traditionally defined as an abdominal or laparoscopic procedure involving mesh fixation to the sacral promontory. The vaginal procedures included in this study were native-tissue ligamentous suspensions, such as

Table 2. Operative and perioperative characteristics by surgical approach

Variable	Abdominal	Laparoscopic	Vaginal	p-value
Operative time >200 min	37.7%	38.1%	14.9%	<0.001
Inpatient procedure	81.2%	18.7%	30.8%	<0.001
Median hospital stay (days, IQR)	2 (1-3)	1 (0-2)	1 (0-2)	<0.001

IQR: Interquartile range

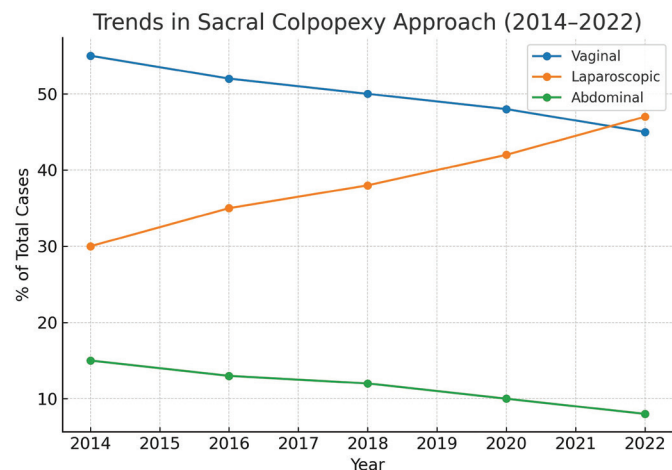


Figure 1. Trends in utilization of surgical approaches for sacral colpopexy from 2014-2022

Line graph showing relative proportions of abdominal, laparoscopic, and vaginal approaches over time

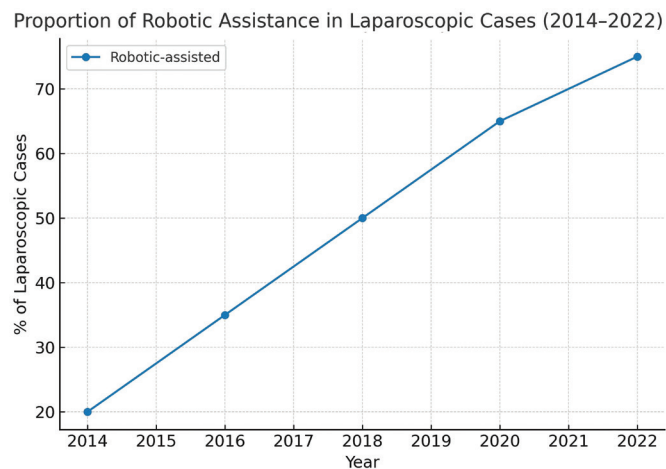


Figure 2. Trends in robotic assistance among laparoscopic sacral colpopexy cases, 2014-2022

Stacked area or line chart showing increase in robotic utilization from 39.2% (2020-2022) to 73.5% in 2022

Table 3. Perioperative complications following sacral colpopexy

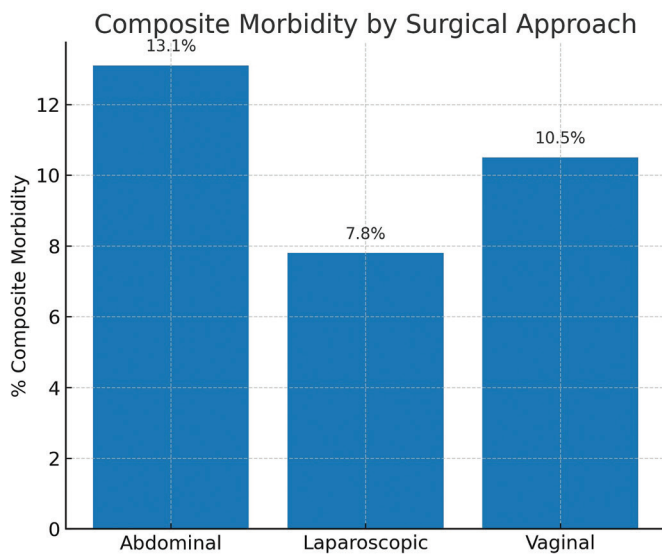
Complication	Abdominal	Laparoscopic	Vaginal	p-value
Composite complication rate	13.1%	7.8%	10.5%	<0.001
Superficial SSI	2.6%	1.2%	1.0%	<0.001
Blood transfusion	4.7%	2.3%	2.4%	<0.001
Readmission	4.7%	2.3%	2.4%	<0.001
Return to OR	2.0%	1.2%	1.4%	<0.001

OR: Odds ratio, SSI: Surgical site infection

Table 4. Adjusted relative risk of composite morbidity by surgical approach

Approach	Adjusted RR	95% CI	p-value
Abdominal (reference)	1.00	–	–
Laparoscopic	0.75	0.67-0.85	<0.001
Vaginal	1.09	0.97-1.21	0.12

RR: Relative risk, CI: Confidence interval

**Figure 3.** Composite complication rates by surgical approach

Bar graph comparing abdominal, laparoscopic, and vaginal routes with percentage complications

uterosacral ligament suspension and sacrospinous ligament fixation. This distinction should be considered when interpreting comparative outcomes across surgical routes.

Comparison with Existing Literature

Historically, abdominal sacrocolpopexy has been regarded as the gold standard for apical prolapse repair, with superior long-term anatomic durability compared with vaginal procedures⁽¹⁾. Landmark studies, including randomized controlled trials, established its effectiveness in reducing recurrent prolapse and improving functional outcomes⁽²⁾. However, open abdominal surgery is associated with higher perioperative morbidity,

longer hospitalization, and slower recovery⁽³⁾. Our findings are consistent with the literature, confirming higher complication rates in the open group than in minimally invasive approaches. The adoption of laparoscopic and robotic-assisted techniques has transformed apical prolapse surgery over the past two decades. Meta-analyses demonstrate that laparoscopic sacral colpopexy achieves equivalent anatomic success compared with the open approach, but with reduced blood loss, shorter hospital stay, and faster return to activities^(4,5). Our data corroborate these advantages, showing the lowest adjusted morbidity in the laparoscopic group. Importantly, robotic assistance within the laparoscopic cohort has expanded substantially in recent years. This trend parallels national utilization studies, which show exponential increases in robotic gynecologic surgery driven by improved surgeon ergonomics, enhanced dexterity, and improved visualization⁽⁶⁾. While our results confirm the safety and feasibility, concerns remain regarding the high costs associated with robotic platforms, without clear evidence of superior outcomes compared to conventional laparoscopy⁽⁷⁾. Vaginal approaches, such as sacrospinous ligament fixation and uterosacral ligament suspension, remain widely used alternatives, particularly in older patients or those with comorbidities, in whom minimally invasive abdominal entry carries higher risks⁽⁸⁾. Several studies suggest that vaginal suspensions offer shorter operative times and the avoidance of general anesthesia, but may be associated with higher recurrence rates and different complication patterns, including buttock pain and ureteric injury⁽⁹⁾. Our findings of intermediate morbidity associated with vaginal colpopexy reflect these trade-offs. These procedures retain an important role in individualized surgical planning, particularly where durability of repair may be balanced against anesthetic and perioperative risks.

Strengths of This Study

A major strength of this study lies in the use of the ACS-NSQIP, a rigorously validated national surgical registry capturing diverse patient populations and outcomes. The large sample size across nearly a decade allowed us to observe temporal trends, evaluate demographic shifts, and assess complication profiles with adequate statistical power. Additionally, adjustment for confounders, such as age, comorbidity burden, and operative time, improves the reliability of comparisons between surgical approaches. The demonstration of increasing robotic adoption in sacral colpopexy adds further relevance, as this reflects current real-world practice and informs future policy regarding surgical innovation.

Study Limitations

Despite these strengths, several limitations must be acknowledged. First, NSQIP captures only 30-day outcomes, preventing assessment of long-term recurrence, mesh-related complications, or functional outcomes such as continence, sexual function, and quality of life. While laparoscopic sacral colpopexy demonstrated a superior perioperative safety profile in this study, its designation as the long-term gold standard rests primarily on durable anatomic outcomes. These long-term measures cannot be assessed within the 30-day follow-up framework of the NSQIP database. These outcomes are central to the ultimate success of prolapse surgery, and their absence limits the comprehensiveness of our conclusions. Second, NSQIP relies on administrative coding, which may misclassify surgical approaches or underreport complications. In particular, robotic procedures are coded within the laparoscopic umbrella, precluding granular analysis of outcomes stratified by robotic versus conventional laparoscopic approaches. Third, we cannot account for surgeon experience, hospital volume, or patient preferences, all of which likely influence surgical approach and outcomes. Finally, selection bias is inherent, as healthier patients may preferentially undergo minimally invasive surgery, while frailer patients may be directed toward vaginal routes.

Clinical Implications

The findings of this study have direct clinical relevance. The superior perioperative safety profile of laparoscopic sacral colpopexy supports its continued adoption as the preferred approach when feasible. The rapid expansion of robotic assistance reflects surgeon and institutional preferences, but the absence of demonstrable outcome superiority underscores the need for cost-effectiveness analyses to guide resource allocation. Vaginal suspension procedures continue to play a vital role, particularly for patients with significant comorbidities or for those in whom minimally invasive abdominal access is contraindicated. These results highlight the importance of individualized patient counseling. Shared decision-making should incorporate patient priorities—

durability of repair, recovery time, avoidance of mesh, or anesthetic risk—alongside evidence-based data on morbidity. For example, a younger, healthier patient seeking long-term anatomic durability may benefit most from laparoscopic sacral colpopexy, whereas an older, medically frail patient may be more appropriately managed with a vaginal approach. The clinical implications of these findings should also be interpreted within the context of healthcare system variability. In regions where access to robotic platforms may be limited compared to the U.S.-based NSQIP population, such as in certain middle-income healthcare systems, conventional laparoscopy or vaginal approaches may remain predominant. Accordingly, surgical decision-making should integrate local resource availability, surgeon expertise, and institutional infrastructure when applying these findings to routine practice.

Future Directions

Future research must address several critical gaps. Long-term comparative studies are needed to evaluate durability, recurrence rates, and functional outcomes across approaches. Particularly, registry data incorporating patient-reported outcomes would provide invaluable insights into quality of life, sexual health, and continence. In parallel, ongoing surveillance of mesh safety remains imperative, given heightened regulatory scrutiny and patient concerns⁽¹⁰⁾. As the utilization of robotics continues to rise, cost-effectiveness analyses must weigh its ergonomic and technical advantages against economic sustainability considerations. Finally, training and dissemination of minimally invasive techniques should be prioritized to ensure equitable access for patients across healthcare systems.

Conclusion

In conclusion, our study demonstrates a clear shift in apical suspension surgery from open abdominal sacral colpopexy to minimally invasive sacral colpopexy, with laparoscopic and robotic-assisted approaches increasingly favored due to their lower perioperative morbidity. Vaginal approaches continue to play an important role in selected patient populations. These findings reinforce the movement toward minimally invasive surgery as the standard of care, while highlighting the need for continued evaluation of long-term outcomes, cost-effectiveness, and patient-centered metrics. Ultimately, optimizing the surgical management of POP requires a balanced, evidence-based approach that integrates evolving technology, clinical outcomes, and patient values.

Acknowledgements

The authors acknowledge the American College of Surgeons National Surgical Quality Improvement Program (ACS-NSQIP) for providing access to the database. The content of this manuscript is solely the responsibility of the authors and does not represent the official views of ACS or NSQIP.

Ethics

Ethics Committee Approval: As this study used de-identified data from the NSQIP database, institutional review board approval and informed consent were not required.

Informed Consent: Not necessary.

Footnotes

Authorship Contributions

Concept: A.B.P., V.P., Design: S.B.S., Data Collection or Processing: A.B.P., V.P., Analysis or Interpretation: S.B.S., Literature Search: S.B.S., Writing: S.B.S.

Conflict of Interest: No conflict of interest was declared by the authors.

Financial Disclosure: The authors declared that this study received no financial support.

References

- Haylen BT, Maher CF, Barber MD, Camargo S, Dandolu V, Digesu A, et al. An International Urogynecological Association (IUGA) / International Continence Society (ICS) joint report on the terminology for female pelvic organ prolapse (POP). *Int Urogynecol J.* 2016;27:165-94.
- Ramesh B, Rani I, Rao KR. Uterovaginal prolapse. In: *Operations in Obstetrics and Gynecology: Text and Atlas.* Jaypee Brothers Medical Publishers (P) Ltd; 2020;134-56.
- DeLancey J. Pelvic floor anatomy and pathology. In: *Biomechanics of the female pelvic floor* Elsevier; 2016. p. 13-51.
- Gyhagen M, Al-Mukhtar Othman J, Åkervall S, Nilsson I, Milsom I. The symptom of vaginal bulging in nulliparous women aged 25–64 years: a national cohort study. *Int Urogynecol J.* 2019;30:639-47.
- Collins S, Lewicky-Gaupp C. Pelvic organ prolapse. *Gastroenterol Clin.* 2022;51:177-93.
- Bo K, Frawley HC, Haylen BT, Abramov Y, Almeida FG, Berghmans B, et al. An International Urogynecological Association (IUGA)/ International Continence Society (ICS) joint report on the terminology for the conservative and nonpharmacological management of female pelvic floor dysfunction. *Int Urogynecol J.* 2017;28:191-213.
- Arnouk A, De E, Rehfuß A, Cappadocia C, Dickson S, Lian F. Physical, complementary, and alternative medicine in the treatment of pelvic floor disorders. *Curr Urol Rep.* 2017;18:1-13.
- Mancini V, d'Altília N, Falagario U, Martino L, Annese P, Busetto GM, et al. Comparison of sacrocolpopexy versus lateral colposuspension in pelvic organ prolapse surgery. *J Urol Ren Dis.* 2022;7:1281.
- Pandeva I, Slack M. Surgical management of complications after urogynaecological surgery. In: *Pelvic floor disorders: a multidisciplinary textbook*; 2021. p. 1097-113.
- Muller N. Pelvic organ prolapse: a patient-centred perspective on what women encounter seeking diagnosis and treatment. *Austr New Zealand Continence J.* 2010;16.