

EARLY DIAGNOSIS OF RUDIMENTARY HORN PREGNANCY AND ITS EXCISION BY LAPAROSCOPY

Ahmet Mete ERGENOGLU, Ahmet Ozgur YENIEL, Nuri YILDIRIM, Sermet SAGOL, Ismail Mete ITIL

Department of Gynecology and Obstetric, Faculty of Medicine, Ege University, Izmir, Turkey

SUMMARY

Rudimentary horn is one of the mullerian canal anomalies, the probability of rudimentary horn pregnancy is between 1/76000 and 1/150000. Usually, it is diagnosed after the rupture. In this case report, a patient who had a cesarean section before and who had an early diagnosis of rudimentary horn pregnancy in the eighth pregnancy week is mentioned. The rudimentary horn is excised by laparoscopy in this patient.

Key words: laparoscopy, mullerian anomaly, rudimentary horn

Journal of Turkish Society of Obstetrics and Gynecology, (J Turk Soc Obstet Gynecol), 2012; Vol: 9 Issue: 1 Pages: 77- 9

RUDİMENTER HORN GEBELİĞİNİN ULTRASONOGRAFİ İLE ERKEN TANISI VE LAPAROSKOPİK EKSİZYONU

ÖZET

Rudimenter horn, müllerian kanal anomalilerinden biri olup rudimenter horn da gebelik sıklığı 1/76000 ile 1/150.000 arasında bildirilmiştir. Tanısı genellikle rüptüre olan gebelikten sonra konulabilmektedir. Vaka sunumumuzda 31 yaşında, öyküsünde sezeryan ile sağlıklı doğumu olan olgunun, rudimenter horn gebeliğinin sekizinci gebelik haftasında ultrasonografi ile erken tanısının konulması ve bu rudimenter horn gebeliğinin laparoskopik olarak eksizyonu bildirilmiştir.

Anahtar kelimeler: laparoskopi, müllerian anomali, rudimenter horn

Türk Jinekoloji ve Obstetrik Derneği Dergisi, (J Turk Soc Obstet Gynecol), 2012; Cilt: 9 Sayı: 1 Sayfa: 77- 9

Address for Correspondence: Ahmet Özgür Yeniel. Ege Üniversitesi Tıp Fakültesi, Kadın Hastalıkları ve Doğum Anabilim Dalı, Bornova, 35100 İzmir
Phone: + 90 (232) 390 17 30
e-mail: drayeniel@hotmail.com

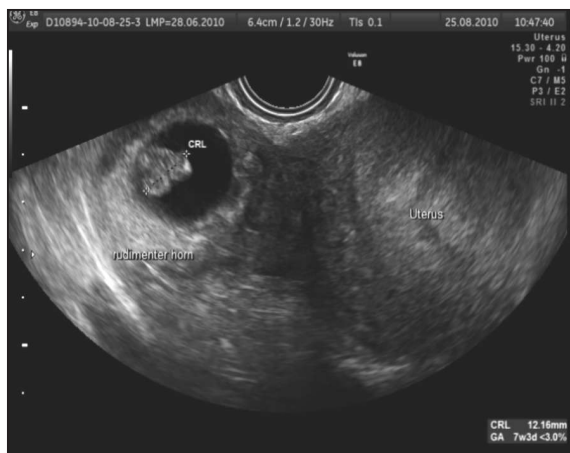Received: 21 September 2010, revised: 21 September 2010, accepted: 15 February 2011, online publication: 08 December 2011

INTRODUCTION

Rudimentary horn is one of the mullerian duct anomalies and the frequency of the rudimentary horn pregnancy is between 1/76,000 and 1/150,000^(1,2). Although there are cases with early diagnosis, most of them are diagnosed after the rupture of the horn. In 80-90% of the cases, rupture of the rudimentary horn occur in between 10th and 20th weeks of gestation^(2,3). After the diagnosis of the rudimentary horn pregnancy, the excision of the rudimentary horn and ipsilateral fallopian tube is necessary.

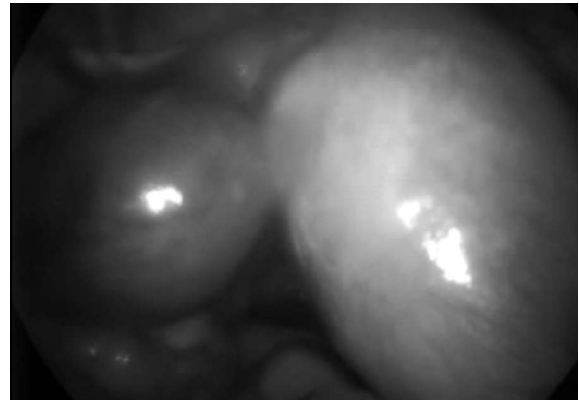
CASE

A thirty-one year old woman with the history of a cesarean section applied with the complaint of delay of menstruation. Her β -hCG level was 93,017 mIU/ml. At transvaginal sonography, a fetus with cardiac activity was determined with CRL: 12,16 mm (gestational age: 7 weeks 3 days old) outside of the uterus at the left side. There was a regular hyperechogenic halo around the gestational sac. Both of the ovaries were normal and there was a minimal free fluid at douglas pouch. At bimanual examination, the size of the uterus was at 2 months gestational age size and there was fullness at the left adnexal region. Her complete blood count and other laboratory examinations were at normal range. She was hospitalized with the diagnosis of pregnancy at 8 weeks and 1 day gestational age. After the examination, the patient claimed that the surgeons mentioned about an accessory uterus next to the uterus after the cesarean section, but they did not make an intervention to it.



Picture 1: The sonographic view of the uterus and the rudimentary horn pregnancy.

Because of the morbidity and mortality risk due to the rupture of the ectopic pregnancy, surgery was planned. Rudimentary horn was excised with the fetus inside with the help of Ligasure(r) via laparoscopy. The left ovary was preserved and the material was taken out via endobag. There was no complication and the patient was discharged the day after surgery.



Picture 2: Laparoscopic view of the uterus and the rudimentary horn.

DISCUSSION

Rudimentary uterine horn consists 3% of mullerian duct anomalies^(4,5). Generally, there is a functional endometrial layer and the horn does not combine with the unicornuate uterus⁽⁶⁾. Pregnancy occurs with the transperitoneal passage of the sperm cell or the fertilized ovum to the rudimentary horn⁽⁷⁾. The frequency of the rudimentary horn pregnancy is between 1/76,000 and 1/150,000^(1,2). Although there are cases with early diagnosis, most of them are diagnosed after the rupture of the horn. The sensitivity of ultrasonography in the diagnosis is 26%⁽⁸⁾. Because there are not strict diagnostic criteria for this rare disease and the experience of the clinician is very important. Tsafir et al. defined some diagnostic criteria for the rudimentary horn pregnancies⁽⁹⁾. These are 1- (1) a pseudopattern of a asymmetrical bicornuate uterus, (2) absent visual continuity tissue surrounding the gestational sac and the uterine cervix, and (3) the presence of myometrial tissue surrounding the gestational sac. Typical hypervascularization of placenta accreta may support the diagnosis. The surgery is necessary after the diagnosis even the rupture has not occurred⁽⁸⁾.

Thus, in this case rudimentary horn pregnancy is

diagnosed at 8th weeks of gestation before the rupture and the horn is excised by laparoscopy.

Whereas, there are different views about the expectant management until the viability of the fetus if there is enough myometrium layer around the gestational sac and if there is emergency surgery conditions⁽¹⁰⁾. This decision is very important. From our point of view, surgery must be offered to the patient because in 80-90% of these cases, rupture occurs between 10th-20th weeks of gestation^(2,3).

Laparotomy was the first choice if the patient had a history of multiple abdominal surgeries or the rupture has occurred, but the laparoscopic experience is increased and nowadays surgeons prefer laparoscopy rather than laparotomy. Laparoscopic horn excisions after the rupture and multiple abdominal surgeries are reported in the literature^(11,12).

In this case, the patient had a history of cesarean section and the rudimentary horn is excised by Ligasure(r). Minimally invasive surgery with laparoscopy is replaced with laparotomy mostly. Additionally, prophylactic excision of rudimentary horn diagnosed incidentally during the abdominal surgery is suggested due to the risk of possible ectopic pregnancy.

As a result, this rare condition is hard to diagnose and the rupture rates are high. After a carefully sonographic examination, a gestational sac with myometrium around outside the unicornuate uterus must suggest a rudimentary horn pregnancy. If the clinician is sure about the diagnosis, surgery is necessary. Laparoscopy seems to be the most appropriate way of surgery in the treatment of rudimentary horn pregnancy. Conflict of interest: None.

REFERENCES

1. Ural SH, Artal R. Third-trimester rudimentary horn pregnancy, a case report. *J Reprod Med* 1998; 37: 919- 21.
2. Naum GG. Rudimentary uterine horn pregnancy. A case report on surviving twins delivered eight days apart. *J Reprod Med* 1997; 42: 525- 32.
3. Edelman AB, Jensen JT, Lee DM, Nichols MD. Successful medical abortion of a pregnancy within a non-communicating rudimentary uterine horn. *Am J Obstet Gynecol* 2003; 189: 886- 7.
4. Jurkovic D, Gruboeck K, Taylor A, Nicolaides KH. Ultrasound screening for congenital uterine anomalies. *Br J Obstet Gynaecol* 1997; 104: 1320- 1.
5. Nahum GG. Uterine anomalies. How common are they, and what is their distribution among subtypes? *J Reprod Med* 1998; 43: 877- 87.
6. Heinonen PK. Unicornuate uterus and rudimentary horn. *Fertil Steril*. 1997; 68: 224- 30.
7. Panayotidis C, Abdel-Fattah M, Leggott M: Rupture of rudimentary horn of a unicornuate uterus at 15 weeks gestation. *J Obstet Gynaecol*. 2004; 24: 323- 4.
8. Jayasinghe Y, Rane A, Stalewski H, Grover S. The presentation and early diagnosis of the rudimentary uterine horn. *Obstet Gynecol* 2005; 105: 1456- 67.
9. Tsafrir A, Rojansky N, Sela HY, et al: Rudimentary horn pregnancy: first trimester pre-rupture sonographic diagnosis and confirmation by magnetic resonance imaging. *J Ultrasound Med*. 2005; 24: 219- 23.
10. Nahum G: Rudimentary horn pregnancy: the 20th century worldwide experience of 588 cases. *J Reprod Med*. 2002; 47: 151- 63.
11. Patrick IO, Harrison A. Pregnancy in a noncommunicating rudimentary horn of a unicornuate uterus: a case report, *Cases Journal* 2009; 3: 6624.
12. Lu J, Anthony S, Bernard C, Laparoscopic excision of rudimentary horn pregnancy in a patient with previous caesarean section, *Arch Gynecol Obstet* 2009; 279: 403- 5.