

PRENATAL ULTRASONOGRAPHIC DIAGNOSIS AND CLINICAL MANAGEMENT OF ACARDIAC TWIN

Yağmur MİNARECİ, Pınar ÇAKMAK, Perran MORÖY, Elif Gül YAPAR, Leyla MOLLAMAHMUTOĞLU,
Nuri DANIŞMAN

Dr. Zekai Tahir Burak Women's Health Education and Research Hospital, Ankara/ Turkey

ABSTRACT

Acardiac twinning is a rare complication of monozygotic twin gestation occurring in 1/35,000 pregnancies, in 1/100 of all monozygotic twins and 1/30 monozygotic triplets. Twin condition is characterized by partial or complete lack of development of the heart in one of the twins, and requires that the normal twin (pump twin) provides circulation for itself as well as the acardiac sibling (recipient twin) by means of reverse circulation through large artery-to-artery and vein-to-vein anastomoses. The acardiac twin is grossly abnormal and the outcome is invariably fatal. Perinatal mortality for the normal twin is about 50-70%, as a result of congestive heart failure, polyhydramnios and preterm delivery.

In this report, we present a case of acardiac twin prenatally diagnosed by ultrasound. The principal sonographic features for prenatal diagnosis and the clinical management are briefly discussed.

Key words: *acardiac acephalic twin, clinical management, prenatal ultrasonographic diagnosis*

ÖZET

Akardiak İkiz Gebeliğin Prenatal Ultrasonografik Tanısı ve Klinik Tedavisi

Akardiak ikiz gebelik; monozigotik ikiz gebeliklerin nadir bir komplikasyonu olup monozigotik ikiz gebeliklerin % 1'inde veya monozigotik üçüz gebeliklerin 1/30' unda yada 35 000 gebelikte bir görülür. Bu durum, ikizlerden birinin kalp gelişiminde komplet veya parsiyel eksikliği ile karakterizedir ve akardiak kardeş (alıcı ikiz) ve kendisi için sirkulasyonu sağlayan normal ikiz'e (pompa ikiz) ihtiyaç gösterir, ters sirkulasyon arter-arter ve/veya ven-ven anastomozları vasıtasıyla olur. Akardiak ikiz ciddi olarak anormaldir ve sonuç daima ölümcüldür. Normal ikiz'in (pompa ikiz) perinatal mortalitesi % 50-70'tir, konjestif kalp yetmezliği, polihidramnios ve preterm eylem sonucuydur.

Bu yayında, ultrasonografi ile prenatal olarak tanı alan bir akardiak gebelik vakasını sunduk. Prenatal tanı için başlıca sonografik özellikler ve klinik tedavi açıkça tartışıldı.

Anahtar kelimeler: *akardiak asefalik ikiz, klinik yönetim, prenatal ultrasonografik tanı*

INTRODUCTION

The development of the acardiac anomaly is a rare complication of monozygotic multiple pregnancies. It was first described in the 16th century (Benedetti,

1533) and occurs in nearly 1/100 of monozygotic twin pregnancies and in one out of 35,000 deliveries and the condition has also been reported to occur in 1/30 monozygotic triplets^(1,2).

It has been hypothesized that this form results from

the fused placentation of monochorionic twins, in which vascular anastomoses arise between the arterial circulation of the hemodynamically advantaged twin (pump twin) to the other one (recipient twin) by means retrograde flow. The recipient twin may display severe and lethal anomalies, including acardia and acephalus. The pump twin is structurally normal but, its expanded cardiac failure and without treatment dies in 50 to 75 percent of cases^(3,4).

CASE REPORT

A 27 year-old woman, gravida 4, para 3; was referred to our institution at 23 weeks of gestation because of a twin pregnancy in which one fetus was suspected to be dead. Real-time ultrasound examination demonstrated monochorionic monoamniotic twin pregnancy with a single posterior placenta; twin A was in breech presentation with fetal measurements consistent with 23 weeks. No abnormalities were noted in this twin. Twin B, had no cardiac activity, had a large amorphus mass containing multiple cystic structures predominantly in the upper portion of the body and generalized edema. There was no evidence of a fetal head structure and of a central cardiac structure. Amniotic fluid volume was increased. (Figure 1) The diagnosis of a fetus acardius acephalus was made. The patient was admitted because of legal termination. Labour was induced by prostoglandin E1 analogs and 12 hours later twins were delivered. The normal twin weighed 600 gr and was a female. APGAR scores at one and five minutes were 1 and 0, respectively.

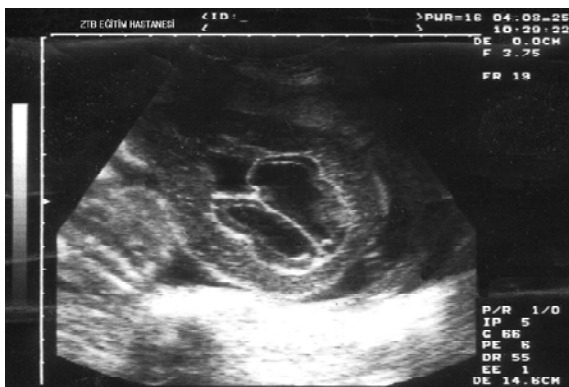

Figure 1: Transverse section through the acardiac twin with the level of the fetal head.

The acardiac twin weighed 680 gr (Figure 2). Upper extremities were absent, the spine and pelvic bones are abnormal; lower limbs were apparent (Figure 3). Eyes were identified, in addition rudimentary ears, mouth and nose were present (Figure 4) and ambiguous genitalia (Figure 5) was observed. Skeleton deformation on X-ray is presented in Figure 6. Autopsy couldn't be done because the family were not give the permission for the autopsy.

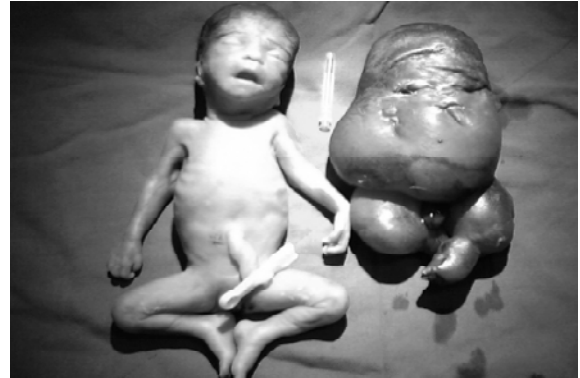

Figure 2: Photograph of the normal (pump) and the recipient twin.

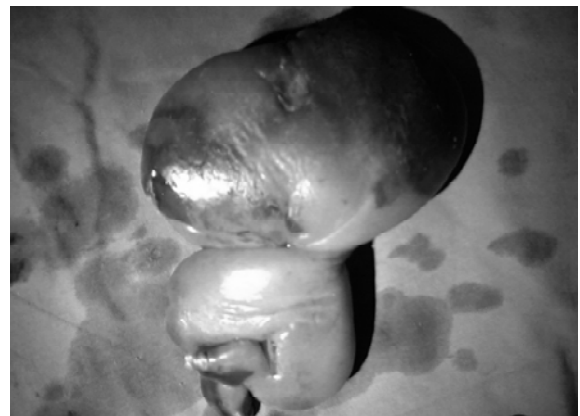

Figure 3: Photograph showing absence of the upper limbs. The lower limbs are developed.

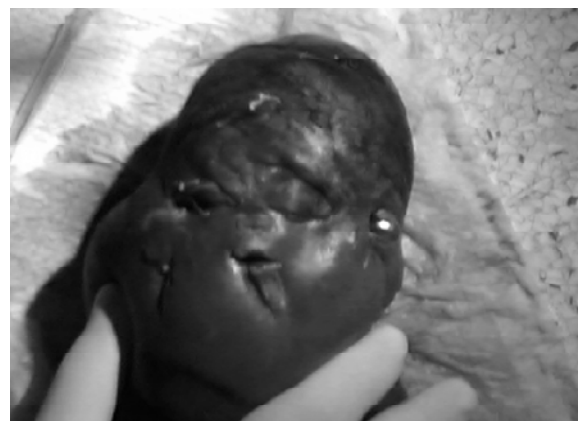

Figure 4: Photograph showing partially developed head and face.

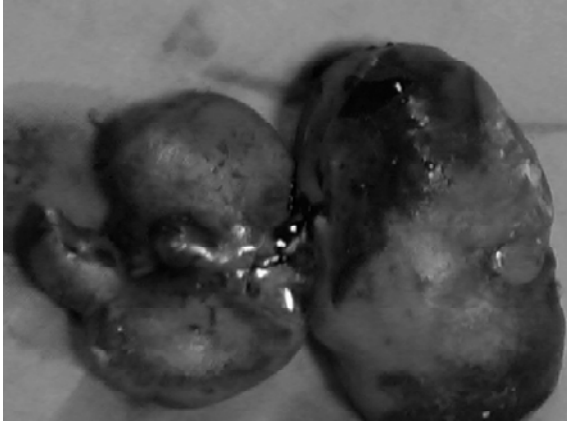


Figure 5: Photograph showing the ambiguous genitalia.

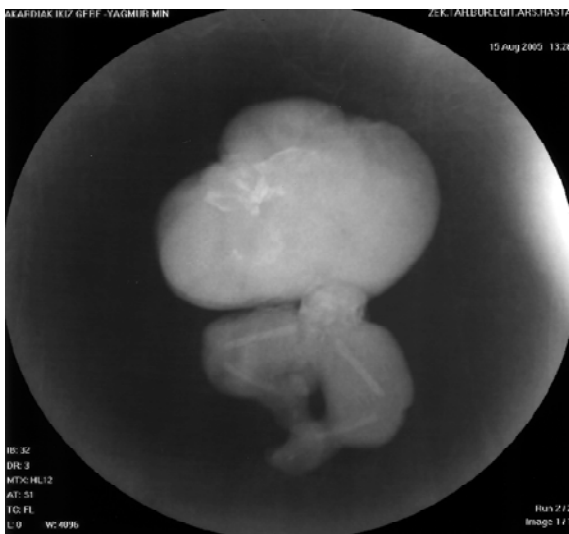

Figure 6: X-ray of the acardiacus showing skeletal deformation: Radiograph showin nonvisualization of the cranial and upper limb bones.

The monoamniotic placenta weighted 180 gr. The normal twin had a three-vessel cord inserted centrally into the placenta. The acardiac twin had a two-vessel cord that was only two cm. in length, attached very close to the placenta in the area of the normal cord. There was a large vessel communicating between two cords.

DISCUSSION

Many different terms have been used to describe the acardiac twin; including monster, parasitic twin, holoacardiac fetus, amorphous twin and some other colorful descriptive names^(5,6). It is very hard to tell a woman that she is carrying a monster or a parasite. Since all these fetuses have no or only a rudimentary cardiac structure and since the etiology is possibly cardiac maldevelopment, the term 'acardiac twin' is

appropriate to describe this anomaly.

The acardiac twin is a unique complication of monozygotic twin gestation in which the normal twin (pump twin) provides circulation for itself as well as the acardiac sibling by means of reverse circulation through large artery-to-artery and vein-to-vein anastomoses⁽⁷⁾. Although the etiology of this condition remains unknown, the most widely accepted hypothesis is the vascular reversal perfusion theory. According to this, large vascular anastomoses develop during early embriogenesis leading to competition between the two circulations. When arterial pressure in one twin exceeds that of the other, reversed circulation in one twin develops, with secondary disruption and reduction of morphogenesis resulting in the cardiac anomaly. Since the perfused twin has no direct vascular connection with the placenta, the blood enters directly through a single umbilical artery and exits through the umbilical vein. Thus pattern of circulation, known as the Twin Reversed Arterial Perfusion (TRAP) sequence, has been recently verified with doppler sonography by several authors. Since the lower part of the body receives beter oxygenated venous blood through the hypogastric artery the most severe abnormalities are always present in the upper part of the body⁽⁸⁻¹¹⁾. The acardiac twin has been classified according to the anomalies found in the four groups: The clinician must be aware that classification may be difficult in certain cases.

1. Acardiacus acephalus: the most frequent form. Cranial portion is absent, upper extremities may not be present and there are rudimentary intrathoracic and intra-abdominal organs.
2. Acardiacus anceps: There is partially developed head and brain tissue, imperfect face, the body and extremities are usually present.
3. Acardiacus amorphus: No recognizable human form: bloblike.
4. Acardiacus acormus: The head is present but the body is absent with an umbilical cord attached to the head or the head directly attached to the placenta.

The categorization into one of the four types does not affect the management and is mainly of academic interest^(2,9,12,13).

Obstetric ultrasonography has made prenatal diagnosis of the acardiac twin possible. Sonographic findings includes absence of cardiac pulsation, amorphous shape of the cephalic pole, poor definition of trunk and

extremities, diffuse subcutaneous edema and abnormal cystic areas in the upper part of the body. Differential diagnoses include large sacrococcygeal teratomas, omphaloceles and intrauterine fetal demise⁽¹⁴⁾. However, prenatal diagnosis of this condition can sometimes be extremely difficult; frequently the acardiac fetus is mistaken for a single fetal demise in a twin pregnancy, and serial sonography is required to establish the correct diagnosis by documentation of growth in the suspected 'dead twin'. Sometimes a heart beat may be seen, which may be a rudimentary heart or the result of the normal twin's cardiac function⁽¹⁴⁻¹⁶⁾.

Many obstetric and neonatal complications are associated with the presence of an acardiac twin. Obstetric complications are: polyhydramnios, preterm labour, cord accidents, dystocia, hydrops fetalis, rupture of the uterus, increased rate of operative deliveries and intrauterine fetal demise. Neonatal complications are: prematurity, twin-to-twin transfusion syndrome. As a result, the normal fetus may develop congestive heart failure and eventually hydrops fetalis^(4,17-19).

Once the diagnosis of acardiac twin is made, management must be focused on the normal twin, who had a perinatal mortality rate of 50% or more^(20,21). Recently Moore et al. have proposed that the weight ratio of acardius to the normal twin may predict congestive heart failure and polyhydramnios in the normal (pump) twin⁽²⁰⁾. With a ratio below 70% it is possible to select a conservative management. If polyhydramnios develops, maternal administration of indomethacin and/or serial amniocentesis have been proposed to reduce amniotic fluid load. If congestive cardiac heart failure develops in normal twin, maternal administration of digoxin can be used successfully. On the other hand, aggressive management options which could improve the survival rate of the normal (pump) twin are available. Selective termination of one fetus is a treatment option in well-selected cases of complicated monochorionic twin pregnancy. Case selection appropriate timing of the procedure, and choice of the optimal technique to be used remain uncertain. When the umbilical cord or major fetal vessels are subjected to obliteration, this should be effected and permanent to arrest fetofetal transfusion and to preclude postmortem interfetal hemorrhage. The different reported techniques balance invasiveness and complexity versus efficacy, and no method clearly superior. Embolization with different thrombogenic

substance has been described, but intrauterine death of both twins has often been observed. Probably caused by incomplete obliteration of all umbilical cord vessels or migration of the substance^(21,22). Conventional fetocide techniques with intracardiac injection of potassium chloride are not an option in monochorionic twin pregnancies because the substance could embolize to the nonaffected twin through the virtually ever-present placental vascular anastomosis. More appropriate techniques aim at arresting the umbilical cord flow completely and permanently. If the occlusion is incomplete or becomes patent over time, persistent fetofetal transfusion or acute agonal interfetal hemorrhage may occur, which is a common event in case of intrauterine fetal death in monochorionic twins. Embolization, neodymium/yttrium-aluminum-garnet (Nd:YAG) laser, monopolar thermocoagulation, bipolar thermocoagulation and fetoscopic ligation are acceptably invasive procedures and have been suggested for this condition; however none of them are universally successful⁽²¹⁻²⁵⁾.

Nd:YAG is a infrared colored and 1,064-1,381 nm wavelengthed laser beam. The energy of this laser, provides tissue coagulation efficiently, is able to penetrate human tissue to depths of 4mm or more. Nd:YAG laser coagulation of the cord can be achieved relatively quickly and easily by using a double-lumen needle to accommodate a fetoscope and a laser fiber. However, it has been shown to have a high failure rate above 20 to 22 weeks of gestational age. Later in gestation, the cord may become too hydroptic, or the vessels may be too large to allow successful coagulation^(26,27).

Monopolar thermocoagulation of the cord has also been attempted once, but it did not arrest umbilical cord flow completely. Whereas, bipolar coagulation is a new alternative technique to occlude the umbilical cord by using available bipolar forceps. This technique simultaneously obliterates both umbilical arteries and the vein, causing immediate cessation of flow, and if effective, it prevents postmortem interfetal hemorrhage through a vessel remaining patent. Also, the procedure can be done through one port. Moreover the technique relies on existing instrumentation and has been shown to be reproducible in different hands. Fetal medicine specialists are familiar with performing invasive procedures under real-time ultrasonographic guidance. Ultrasonographic guidance also permits the procedures in conditions in which fetoscopy is difficult such as

particles or blood. Bipolar coagulation is a well-known, easy and readily available energy modality and needed generators are present in any modern operating room. Unlike the monopolar coagulation technique, It also has the theoretic advantage that the electrical current does not travel through the umbilical cord, the placenta, or the body of the other twin because bipolar current passes only between the two blades of the instrument. Compared with the cord ligation, the duration of the procedure is markedly reduced⁽²⁸⁻³¹⁾.

Fetoscopic cord ligation achieves complete and permanent arterial and venous occlusion, with survival rates of about 70%. The procedure is relatively complex and lengthy, and even in experienced hands it fails in about 10% of cases. Moreover postoperative rupture of the membranes occurs in over 30% of cases and is therefore a major drawback. This is much higher than the 10% preterm prelabor rupture of the membranes rate observed after other fetoscopic interventions, such as laser coagulation of the chorionic plate vessels for twin-to-twin transfusion syndrome⁽³²⁾. It has been speculated that a higher risk of preterm prelabor rupture of the membranes after cord ligation is related to the complexity of the procedure, the higher number of ports and longer operating times⁽³³⁾. For all of these reasons, a simpler but equally effective technique for the cord obliteration would be wellcomed.

Alcohol injection is a noninvasive technique which has been used for management of acardiac twin pregnancies. Sepulveda et al. were the first to report ablation of a 23-week acardiac twin by alcohol injection into the intraabdominal portion of the umbilical artery under direct ultrasonographic guidance⁽³⁴⁾. The relative lack of invasiveness with this percutaneous technique requiring no special instrumentation was compelling. The risks of this technique is minimal because it is analogous to other end-organ or appendage ablations used by interventional radiology. The possibility of aliquots of alcohol migrating upstream from a properly positioned needle into critical areas of the pump twin's circulation is remote^(35,36).

Other technique which is selective delivery of the acardiac twin by hysterotomy and continuation of the pregnancy for the normal twin has been reported⁽²⁹⁾. Chromosomal analysis of the acardiac twin has usually been normal. However several cases of abnormal karyotypes have been reported on⁽³⁷⁾. In our case, we found a normal (46 XX) karyotype.

In summary, the acardiac anomaly is a high-risk condition with exceedingly high perinatal mortality for the normal twin. No general consensus exists on the management of a pregnancy complicated by an acardiac twin. Many of these pregnancies are delivered prematurely because of polyhydramnios, preterm labour and premature rupture of membranes. A conservative approach seems reasonable. Serial amniocentesis may be needed for symptomatic polyhydramnios. Preterm labour precautions are necessary, as with any other kind of twin pregnancy. Fetal therapy may be indicated for complications secondary to the twin to twin transfusion syndrome. This report emphasizes the role of ultrasonography for early intrauterine diagnosis of acardiac acephalic twin and the management procedure of this syndrome; Early diagnosis may enhance rational management scheme for improving the prognosis of the normal (pump) twin.

REFERENCES

1. James WH. A note on the epidemiology of acardiac monsters. *Teratology* 16. 1977; 211.
2. Napolitani FD, Schreiber I. The acardiac monster. A review of the world literature and presentation of 2 cases. *Am J Obstet Gynecol* 1960; 80: 582.
3. Acton CM, Woodward CS. Acardia twins. *Australas Radiol* 1993; 37: 389.
4. Pinet C, Colau JC, Delezoide AL et al. Acardiac twins. *J gynecol Obstet Biol Reprod* 1994; 23: 85.
5. Boronow RC, West RH. Monster acardius parasiticus. *Am J Obstet Gynecol* 1964; 88: 233.
6. Richart R, Benirschke K. Holoacardius amorphus: Report of a case with chromosome analysis. *Am J Obstet Gynecol* 1962; 86: 329.
7. Nicolaidis P, Nasrat H, Tannirandorn Y. Fetal acardis: etiology, pathology and management. *J Obstet Gynecol* 1990; 10: 518.
8. Van Allen MI, Smith DW, Shepard TH et al. Twin reversed arterial perfusion (TRAP) sequence: a study of 14 twin pregnancies with acardius. *Semin Perinatol* 1983; 7: 285.
9. Sepulveda W, Quiroz V, Giuliano A et al. Prenatal ultrasonographic diagnosis of acardiac twin. *J Perinat Med* 1993; 21: 241-246.
10. Malhotra N, Sinha A, Deka D. Twin reversed arterial perfusion: report of four cases. *J Clin Ultrasound*. 2004 Oct; 32(8): 411- 4.
11. Sohi I, Chacko B, Masih K, Choudhary S. A case of TRAP sequence: acardiac twin. *Indian J Pathol Microbiol*. 2003 Oct; 46(4): 664- 5.
12. Czichos E, Krekora M, Kulig A et al. Acardiac fetus—morphological

- and clinical aspects. *Pol Merkuriusz Lek.* 2005 Jan; 18(103): 82-4. Polish.
13. Rajesh B, Mahadhevan B, Rao S et al. Acephalus acardiac fetus. *Indian J Pediatr.* 2004 Oct; 71(10): 948. Review
 14. Reuhland RG, O'Leary JA, Ferrell RE. The holocardius acephalus twin: prenatal diagnosis. *Am J Perinatol* 1886; 3: 33.
 15. Coulam CB, Wright G. First trimester diagnosis of acardiac twins. *Early Pregnancy.* 2000 Oct; 4(4): 261- 70.
 16. Spencer R. Parasitic conjoined twins: external, internal (fetuses in fetu and teratomas), and detached (acardiacs). *Clin Anat.* 2001 Nov; 14(6): 428- 44. Review.
 17. Mohanty C, Mishra OP, Singh CP, Das BK. Acardiac anomaly spectrum. *Teratology.* 2000 Nov; 62(5): 356- 9.
 18. Mastrobattista JM, Silva JB. Case 7: obstetrical. Acardiac twinning. *J Ultrasound Med.* 2000 May; 19(5): 359.
 19. Brassard M, Fouron JC, Leduc L et al. Prognostic markers in twin pregnancies with an acardiac fetus. *Obstet Gynecol.* 1999 Sep; 94(3): 409- 14.
 20. Moore TR, Gale S, Bemirschke K. Perinatal outcome of forty-nine pregnancies complicated by acardiac twinning. *Am J Obstet Gynecol* 1990; 163: 907.
 21. Deprest JA, Audibert F, Hecker K et al. Bipolar coagulation of the umbilical cord in complicated monochorionic twin pregnancy. *Am J Obstet Gynecol.* 2000 Feb; 182(2): 340- 5.
 22. Porreco R, Barton SM, Haverkamp AD. Occlusion of umbilical artery in acardiac acephalic twin. *Lancet* 1991; 337: 326- 7.
 23. Grab D, Scheider V, Keckstein J et al. Twin, acardiac, Outcome. *Fetus* 1992; 2: 11- 13.
 24. Roberts RM, Shah DM, Jeanthy Pet al. Twin, acardiac, ultrasound-guided embolization. *Fetus* 1991; 1: 5- 10.
 25. Holzgreve W, Tercanli S, Krings W. A simpler technique for umbilical cord blockade of an acardiac twin. *N Engl J Med* 1995; 331: 57- 8.
 26. Ville Y, Hyett J, Vandenbussche FPHA, Niclolaides KH. Endoscopic laser coagulation of umbilical cord vessels in twin reversed arterial perfusion sequence. *Ultrasound Obstet gynecol* 1994; 4: 396- 8.
 27. Hecher K, Reinhold U, Gbur K, Hackelöer B-J. Interruption of umbilical blood flow in an acardiac twin by endoscopic laser coagulation. *Geburtshilfe Frauenheinkd* 1996; 56: 97- 100.
 28. Porreco RP. Percutaneous ultrasonographically guided ablation of an acardiac twin. *Am J Obstet Gynecol.* 2004 Feb; 190(2): 572- 4.
 29. Sullivan AE, Varner MW, Ball RH, Jackson M. The management of acardiac twins: a conservative approach. *Am J Obstet Gynecol.* 2003 Nov; 189(5): 1310- 3.
 30. Rodeck C, Deans A, Jauniaux E. Thermocoagulation for the treatment of pregnancy with an acardiac twin. *N Engl J Med* 1998; 339: 1293- 4.
 31. Quintero RA, Romero R, Reich H et al. In utero percutaneous umbilical cord ligation in the management of complicated monochorionic multiple gestations. *Ultrasound Obstet Gynecol* 1996; 8: 16- 22.
 32. Ville Y, Gagnon A, Sebire N et al. Endoscopic laser coagulation in the management of severe twin twin transfusion syndrome. *Br J Obstet Gynecol* 1998; 105: 446- 53.
 33. Deprest J, Lerut T, Vandenberghe K. Endoscopic fetal surgery: a new perspective in fetal surgery? *Prenat Diagn* 1997; 17: 1247- 60.
 34. Sepulveda W, Bower S, Hassan J. Ablation of acardiac twin by alcohol injection into the intra-abdominal umbilical artery. *Obstet Gynecol* 1995; 86: 680- 1.
 35. Tan TY, Sepulveda W. Acardiac twin: a systematic review of minimally invasive treatment modalities. *Ultrasound Obstet Gynecol.* 2003 Oct; 22(4): 409-19. Review.
 36. Sepulveda W, Corral E, Otano L et al. Intrafetal alcohol chemosclerosis of acardiac twins: a multicenter experience. *Fetal Diagn Ther.* 2004 Sep-Oct; 19(5): 448- 52.
 37. Bieber FR, Nance WE, Morton CC et al. Genetic studies of an acardiac monster: evidence of polar body twinning in man. *Science.* 1981 Aug 14; 213(4509): 775- 7.