

A CASE OF SEVERE PEMPHIGOID GESTATIONIS WITH CENTRAL NERVOUS SYSTEM PATHOLOGY IN THE NEWBORN AND REVIEW OF THE LITERATURE

Aydan BİRİ, Banu ÇİFTÇİ, Güven GÜNAYDIN, Ümit KORUCUOĞLU, Nuray BOZKURT, Ahmet ERDEM

Department of Obstetrics and Gynecology, Gazi University Faculty of Medicine, Ankara, TURKEY

SUMMARY

A case of severe Pemphigoid Gestationis (PG), persisted postpartum despite high-dose corticosteroid therapy was reported. Small for gestational age, premature birth, and neonatal convulsions with confirmed central nervous system pathology occurred as an adverse fetal outcome. Is the disease as innocent as described earlier?

Key words: dermatose, herpes gestationis, pemphigoid gestationis

ÖZET

Yenidoğanda Santral Sinir Sistemi Patolojisinin Eşlik Ettiği, Şiddetli Seyreden Pemphigoid Gestasyon Olgusu ve Literatürün Gözden Geçirilmesi

Yüksek doz kortikosteroid tedavisine rağmen, postpartum dönemde de şiddetli seyreden Pemphigoid Gestasyon (PG) olgusu sunulmuştur. Fetal sonuçlar olarak, SGA, prematür doğum ve santral sinir sistemi patolojisinin doğrulandığı neonatal konvülsiyonlar izlenmiştir. Hastalık önceden belirtildiği kadar masum mudur? Bu çalışmada bu hastalığın prognozu ve tedavisi ile ilgili literatür tartışılmıştır.

Anahtar sözcükler: dermatoz, herpes gestasyonis, pemphigoid gestasyon

INTRODUCTION

Pemphigoid Gestationis (PG) is a rare autoimmune bullous disease that is associated with pregnancy and rarely with trophoblastic malignancy. On the grounds that this pregnancy-associated bullous dermatosis is not caused by any herpes virus and has much in common with the immunologically mediated disorder "Bullous Pemphigoid"; the new term "Pemphigoid Gestationis(PG)" instead of the old term "Herpes Gestationis" was proposed. The incidence of PG is estimated between 1 in 10000 and 1 in 50000

pregnancies. We report a case of severe PG, which required hospitalization during several months even after delivery and resulted significant decrease in patient's quality of life due to high-dose and multiple medications. Besides a premature and intrauterine growth restricted fetus; temporary neonatal convulsions and pathological electroencephalography findings together with vesicular eruptions in early neonatal periods were observed. Present report indicates that most likely because of passive transfer of PG antibody, the disease may affect central nervous system of the newborn, in addition to the skin.

Adress for Corresponding: Banu ÇİFTÇİ, Gazi Üniversitesi Tıp Fakültesi Kadın Hastalıkları ve Doğum Anabilim Dalı, Beşevler\ANKARA, TURKEY

Tel: (0312) 202 59 43

Fax: (0312) 215 77 36

e-mail: guven22@yahoo.com

Alındığı tarih: 01. 07. 2005, kabul tarihi: 18. 07. 2005

CASE

A 42-year-old woman (gravida six, parity three, abortion two) at 20 weeks' gestation presented with extremely pruritic, blistering skin eruption localized around the umbilicus (Figure 1) and vulva. In her obstetrical history, there were two spontaneous abortions, two vaginal births and one preterm birth in 34th weeks in which similar but mild eruptions occurred at the beginning of the third trimester. There were no other risk factors to explain the preterm birth.

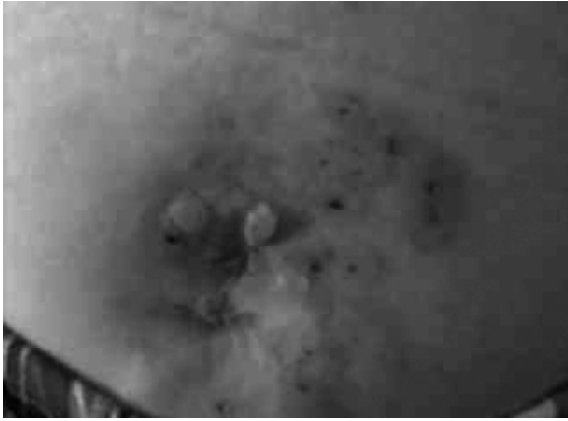

Figure 1: Abdominal lesions on presentation.

Lesions were polymorphic with urticaria-like erythematous and edematous papules, plaques, tense vesicles and bullae. Multiple skin biopsies were obtained and PG was confirmed as histopathological diagnosis after a sample processed for direct immunofluorescence. Subepidermal edema, vesicle, and perivascular infiltrate of lymphocytes, histiocytes and eosinophils were reported as histopathologic features (Figure 2).

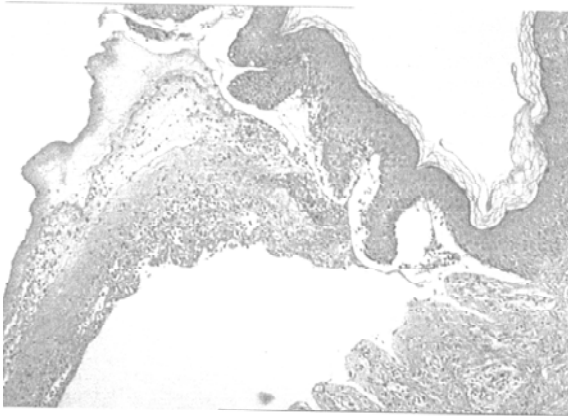


Figure 2: The skin biopsy from lesions (x 10, H&E).

Pruritus was quite severe. No relief obtained from topical corticosteroids and antihistamines. Despite

administration of the oral prednisone, a generalized bullous reaction ensued that spares the face, mucous membranes, and palms and soles (Figure 3, 4).

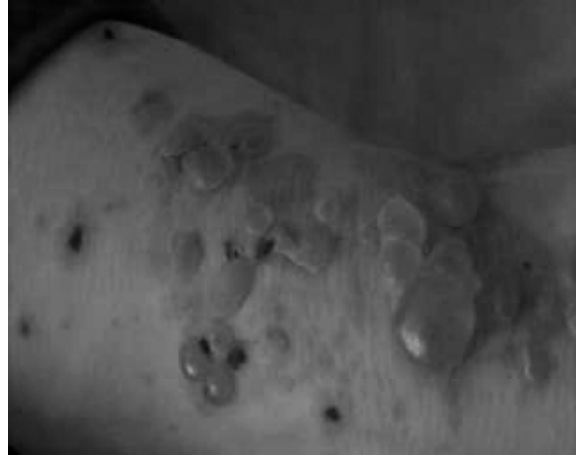

Figure 3: No improvement following corticosteroid therapy (antecubital area).

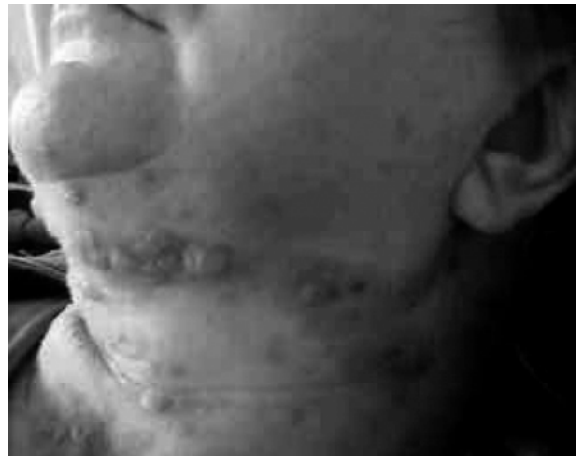

Figure 4: No improvement following corticosteroid therapy (neck)

Fluocortolone orally started and doses up to 60 mg daily administered. Doses regulated according to exacerbations and remissions throughout pregnancy. She delivered a viable infant at 35 weeks' gestation following preterm premature rupture of the membranes. She continued to have recurrent severe symptoms during the peripartum and postpartum period. The patient required hospitalization in dermatology department and high-dose corticosteroid treatment applied, until remission observed in postpartum 12th weeks.

Antenatally, when presented, in 20th weeks' gestation, there was no problem in both biometry and anatomic survey of the fetus. The woman despite advanced maternal age has not accepted amniocentesis. In the

ultrasound examination performed in 29th weeks, estimated fetal weight was in 10 percentiles. At 34 weeks' gestation, estimated fetal weight was between 5 and 10 percentiles. Following preterm premature rupture of the membranes, she delivered a viable infant at 35 weeks with cesarean electively. The male neonate was 2120 g (10. percentile) with 1st minute and 5th minute apgar scores of 7 and 8, respectively. Clinical confirmation of prematurity and small for gestational age diagnoses were made.

At postpartum 2nd day papulo-vesicular eruptions similar with mothers lesions observed in the newborn on the forehead and facial region but they disappeared in a few days without any treatment. Because of lack of the parents consent, biopsy was not taken from eruptions. At the sixth day of life myoclonic jerks developed. Electroencephalography (EEG) examination revealed partial epileptic activity on both hemispheres, but no abnormal findings were observed in the cranial ultrasonography and magnetic resonance imaging. Following phenobarbital therapy, convulsions disappeared and control EEG was normal at postnatal 30th day when anticonvulsant therapy was discontinued

DISCUSSION

PG is an autoimmune organ-specific blistering skin disease⁽¹⁾. It occurs only in the presence of placental tissue. The incidence was reported about 1 in 50,000 pregnancies⁽¹⁾. In our case, disease course was so severe that patient's quality of life was severely impaired despite multiple and high dose medication. In addition to the estimated growth restriction and prematurity, convulsions of undetermined etiology were observed in the early neonatal period, which we couldn't find such an adverse fetal outcome in the literature.

The disease manifests itself most commonly during the second or third trimester with an average onset at 21 weeks, although in 20% of patients initial onset occurs in the immediate postpartum period⁽²⁾. Our patient presented at 20 weeks' gestation. In her fourth pregnancy, same lesions attributable to the same disease did so later and less severe and skip pregnancy occurred for which there has been no satisfactory explanation could be done in the literature⁽³⁾. Although our patient had advanced maternal age, no such association was described. We could easily make a presumptive diagnosis of PG

in the case with a typical distribution of vesicles and bulla. The typical blistering eruption had a herpetiform appearance, but the vesicles were not clustered and were located more peripheral than herpes. Skin biopsy, including a sample processed for direct immunofluorescence, confirmed the diagnosis. This confirmation distinguished PG from polymorphic eruption of pregnancy, which does not recur with subsequent pregnancies.

In the cases reported, the disease runs a variable clinical course. A flare at the time of delivery is a typical feature, seen in 75% of cases and in most patients; the disease spontaneously regresses in the postpartum period. Many patients with PG transiently improve during the last 6 to 8 weeks of pregnancy only to experience an uncomfortable flare of their disease within 24 to 48 hours after delivery⁽²⁾. Nevertheless, in the present case although the flare had occurred peripartum, the disease persisted during the course of the pregnancy and the postpartum period. The bullous, extremely pruritic lesions persisted 12 weeks. We could not find association between severity of the disease and the perinatal outcomes in the previous reports. Moreover, the effects of breast-feeding and prolactin on prolonging the duration of PG deserve further investigation⁽⁵⁾.

It is suspected that elevated hormone levels during pregnancy are causative since progestin can induce exacerbations. Protracted courses, recurrence with menses or subsequent use of oral contraceptives and conversion to bullous pemphigoid have been reported⁽⁵⁾. The increased frequency of certain histocompatibility locus antigens (HLA) in women with PG suggests a genetic predisposition. This autoimmune disease is caused by development of an antibody to the basement membrane zone (anti-BMZ) in the epidermis. There is an inherited predisposition with a markedly increased incidence of HLA-DR3 and HLA-DR4 antigens in affected women^(3, 4, 6-12). An increased risk of autoimmune diseases, in particular Graves' disease has been reported in patients with a history of PG. Shornick and Black reported that 10 % of 75 women with PG also had Grave's disease⁽⁴⁾. There have been no other maternal risks in PG. No known associate autoimmune disease was observed in our case.

Early urticarial lesions responded to topical corticosteroids and antihistamines but lesions that were more advanced required systemic corticosteroid therapy.

Although doses up to 180 mg of prednisone daily have been reported, most patients respond to lower doses (20-40 mg daily). Orally administered prednisone, did not bring relief promptly and inhibit formation of new lesions in our case and with improvement of clinical symptoms following administration of fluocortolone and no new bulla formation, the dose then had tapered. Refractory cases during the postpartum period had been reported that respond to adjunctive cyclophosphamide, pyridoxine, gold or methotrexate^(13, 14, and 15). Intravenous immunoglobuline combined with cyclosporine, plasmapheresis, chemical oophorectomy with goserelin, and ritodrine have been exceptionally used in chronic PG with some success. However, because the response to these agents has been variable and their safety questionable, we have not administered additional therapy to the high-dose corticosteroids. Because in the postpartum period patient had experienced a flare of pemphigoid gestationis requiring continued steroids, prednisone doses of 20 mg/day still was allowed safe breast-feeding.

Prior to the development of immunologic techniques that permitted an accurate diagnosis, PG was believed to have minimal adverse effects on the fetus⁽¹⁶⁾. In 1969, Kolodny reported no increase in preterm births, stillbirths, or abortions⁽¹⁷⁾. However, Lawley et al. subsequently reviewed 40 immunologically proven cases of PG and documented serious fetal morbidity and mortality: preterm births occurred at a rate of 22 percent and three women suffered stillbirths⁽¹⁸⁾. These authors suggested that high levels of circulating antibasement membrane antibody and peripheral eosinophilia caused the increased fetal risk. The pathophysiology of fetal complications was thought to be due to mild placental insufficiency, because placental antigens may be targeted by the immune responses that target the skin. Shornick and Black described 74 patients with PG confirmed by immunofluorescence studies⁽⁵⁾. They found an increased frequency of fetal growth restriction and prematurity, but not stillbirth or miscarriage⁽⁵⁾. No evidence currently exists to determine whether systemic therapy for PG reduces the risk of fetal prematurity. In the present report, all adverse perinatal outcomes reported that had association with the disease had been observed; premature birth, small for gestational age and neonatal transient eruptions. Nevertheless, it is the first case in the literature that central nervous system pathology, which has been

confirmed with EEG findings, had reported. These convulsions may not have any association with the disease but, they were transient and no other metabolic or the other etiologies have been found so it can be suggested that this clinic finding may be result of PG antibody, which crosses placenta passively. In addition to the placenta and skin, same antibodies may have cross-reactions with neuronal tissue, too. Neonatal vesicles occur in 10% of cases, most likely because of passive transfer of PG antibody⁽¹⁵⁾. The eruption is usually mild and self-limited; like our case but the lesions may become super infected as the immune system of the neonate is not fully developed. Still once the diagnosis of PG is established, the pregnancy should be considered high risk. In addition, close surveillance is required for the possible adverse fetal effects. The patient had to be counseled about the recurrence risk of pregnancies in the future.

REFERENCES

1. Engineer L, Bhol K, Ahmed AR. Pemphigoid gestationis: A review. *Am J Obstet Gynecol* 2000;183:483.
2. Jenkins RE, Hem S, Black MM. Clinical features and management of 87 patients with pemphigoid gestationis. *Clin Exp Dermatol* 1999;124:255.
3. Holmes RC, Black MM. Herpes gestationis. *Dermatol Clin* 1987;1:195.
4. Shornick JK. Herpes gestationis. *J Am Acad Dermatol* 1987; 17:539.
5. Shornick JK, Black MM. Fetal risks in herpes gestationis. *J Am Acad Dermatol* 1992;26:63.
6. Garcia-Gonzalez E, Castro-Llamas J, Karchmer S. Class II major histocompatibility complex typing across the ethnic barrier in pemphigoid gestationis. A study in Mexicans. *Int J Dermatol* 1999;38:46.
7. Jordon ER, Heine KG, Tappeiner G. The immunopathology of herpes gestationis: immunofluorescence studies and characterization of "HG factor." *J Clin Invest* 1976;57:1426.
8. Morrison LH, Labib RS, Zone JJ. Herpes gestationis autoantibodies recognize a 180-kD human epidermal antigen. *J Clin Invest* 1988;81:2023.
9. Mutasim DF, Takahashi Y, Labib RS. A pool of bullous pemphigoid antigen(s) is intracellular and associated with the basal cell cytoskeleton-hemidesmosome complex. *J Invest Dermatol* 1985;84:47.
10. Guidice GJ, Emery DJ, Zelickson BD. Bullous pemphigoid

- and herpes gestationis autoantibodies recognize a common non-collagenous site on the BP 180 ectodomain. *J Immunol* 1993;151:5742.
11. Liu Z, Diaz LA, Swartz SJ. Molecular mapping of pathogenically relevant BP180 epitope associated with experimentally induced murine bullous pemphigoid. *J Immunol* 1995;155:5449.
 12. Satoh S, Seishima M, Sawada Y. The time course of the change in antibody titres in herpes gestationis. *Br J Dermatol* 1999; 140:119.
 13. Fine JD. Management of acquired bullous skin diseases. *N Engl J Med* 1995;333:1475.
 14. Castle SP, Mather-Mondrey M, Bennion S, David-Bajar K, Huff C. Chronic herpes gestationis and antiphospholipid antibody syndrome successfully treated with cyclophosphamide. *J Am Acad Dermatol* 1996;34:333.
 15. Paternoster DM, Bruno G, Grella PV. New observations on herpes gestationis therapy. *Int J Gynaecol Obstet* 1997;56:277.
 16. Caruthers JA. Herpes gestationis: clinical features of immunologically proven cases. *Am J Obstet Gynecol* 1978;131:865.
 17. Kolodny R. Herpes gestationis: a new assessment of incidence, diagnosis, and fetal prognosis. *Am J Obstet Gynecol* 1969; 104:39.
 18. Lawley TJ, Stingl G, Katz SI. Fetal and maternal risk factors in herpes gestationis. *Arch Dermatol* 1978;114:552.

Düzelme

Uzmanlık Sonrası Eğitim ve Güncel Gelişmeler Dergisi 2005 yılı Cilt 2, Sayı 2, 103-106. sayfalarda yayınlanan makalede yazarlardan Dr. Aydan Biri'nin adı baskıda görülmemiştir. Düzeltilmiş yazar adları ve sırası aşağıdaki gibidir. Durumu bildirir, özür dileriz.

RALOXIFENE KULLANIMININ CİNSEL FONKSİYON ÜZERİNE ETKİSİ.

Araş. Gör. Dr. Banu ÇİFTÇİ*

Y. Doç. Dr. Aydan BİRİ*

Doç Dr. Ahmet ERDEM*

Doç. Dr. Mehmet ERDEM*

Prof. Dr. Özdemir HİMMETOĞLU*

Prof. Dr. Mülazım YILDIRIM*

*Gazi Üniversitesi Tıp Fakültesi Kadın Hastalıkları ve Doğum Anabilim Dalı

Uzmanlık Sonrası Eğitim ve Güncel Gelişmeler Dergisi 2005 yılı Cilt 2, Sayı 2, 103-106.