

SIGMOID COLON RESECTION DUE TO ENDOMETRIOMA: REPORT OF A CASE

Pinar Solmaz YILDIZ*, **Fuat AKERCAN***, **Teksin CIRPAN***, **Ismail Mete ITIL***,
Basak DOGANAVSARGIL**, **Sait YUCEBILGIN***

* Department of Obstetrics and Gynecology, Ege University Faculty of Medicine, Izmir, Turkey

** Department of Pathology, Ege University Faculty of Medicine, Izmir, Turkey

SUMMARY

Endometriosis at sigmoid colon is a rare but important phenomena because of the differential diagnosis of malignancy. We report a 48-year-old patient with a nonspecific abdominal pain patient who was thought to have gastrointestinal malignancy initially and later diagnosed as endometriosis at the sigmoid colon.

Key words: endometriosis, sigmoid colon

ÖZET

Endometrioma nedeniyle sigmoid kolon rezeksiyonu: Olgu sunumu

Sigmoid kolon endometriosisi az görülen fakat maligniteden ayrılması gereği nedeniyle önem içeren bir fenomendir. Gastrointestinal malignite düşünülen fakat kesin tanısı sigmoid kolon endometriosisi gelen, spesifik olmayan karın ağrısı ile başvuran, 48 yaşındaki hasta sunulmaktadır.

Anahtar kelimeler: endometriosis, sigmoid kolon

INTRODUCTION

Endometriosis is a disorder which abnormal growth of endometrial tissue in locations other than the uterine lining. Although endometriosis can occur very rarely in postmenopausal women, it is found almost exclusively in women of reproductive age. The lesions are usually found on the peritoneal surfaces of the reproductive organs and adjacent structures of the pelvis, but they can occur anywhere in the body. Its exact prevalence is unknown because the surgery is required for its diagnosis, but it's estimated to be present in 3- 10% of reproductive age women and 25- 35% of infertile women⁽¹⁾. The cause of endometriosis is unknown. The leading theories include retrograde

menstruation with transport of endometrial cells, metaplasia of coelomic epithelium and lymphatic or hematogenous spread of endometrial cells. A combination of this theories is likely to be responsible. The role of immun system or the genetic tendency have been described in subsequent studies. The most common site of disease is ovary (approximately 50% of cases), followed by the uterin cul-de-sac, uterosacral ligaments, the posterior surfaces of the uterus and broad ligament and the remaining peritoneum. The most common extragonadal manifestations are the rectosigmoid and the rectovaginal septum⁽²⁾. While implants occur over the bowel, bladder and ureters; rarely they may erode into underlying tissue and cause blood in the stool or urine, or their associated adhesions

Adress for Corresponding: Fuat AKERCAN M.D. Department of Obstetrics and Gynecology, Ege University Faculty of Medicine,
35100-Bornova, Izmir , TURKEY

Fax: (232) 343 07 11 / e-mail: akercan@med.ege.edu.tr

Received: 8. 4. 05, Accepted: 13. 5. 05

may result in stricture and obstruction of these organs. Endometrioma should be considered in the differential diagnosis of pelvic mass⁽³⁾.

Although endometriosis resembles the uterine endometrium histologically, simultaneous biopsies of implants and endometrium have found the implants often to be out of phase with the uterine tissue. Also the characteristic changes of estrogen and progesterone receptors present in endometrium across the menstrual cycle are absent in endometriosis implants.

CASE REPORT

A 48-year-old woman presented with the complaint of abdominal pain. She was fertile and had regular menses. Physical examination revealed tenderness in lower abdominal quadrants. The examination of the genital system was normal. Routine chemistry and the hemogram of the patient were in normal range. Tumor markers were as follows: CA125: 81 U/mL (normal range <35), CA19-9: 56 U/mL (normal range <39), the CEA CA15-3, AFP were in normal range. In the pelvic sonography the uterus and the ovaries were normal. Colonoscopy revealed a normal mucosal lining of the colon but an external compression at the beginning of sigmoid colon was marked. In the abdominal computerised tomography scanning an increase of the wall thickness and a partial obstruction at the level of the sigmoid colon was noted. These findings let us to think the case as a primary sigmoid tumor. Rectum and the perirectal fat tissue plans were normal and no pathological lymphadenopathy was observed on computerised tomography. Cervical cytology was within normal limits.

The patient underwent a laparotomy. The uterus was in normal size and the ovaries were atrophic, there were no macroscopic lesion of endometriosis. The left tuba uterina had adhesions with the sigmoid colon and there was a nearly 30 mm palpable lesion in the sigmoid colon next to rectum. Segmental sigmoid colon resection and sigmoidorectal anastomosis was performed by a general surgeon. The result of the frozen section was benign (endometrioma). In pathologic evaluation; when the 13 cm. long resected segment opened along the antimesenteric border, mucosa found to be almost normal apart from a small area of erosion. Serial section

of the bowel wall revealed the presence of cystically dilated hemorrhagic lesions in submucosa and muscularis propria measuring 2 cm. long in greatest diameter (Figure 1). Microscopically these discrete brownish foci were consistent with “ectopic” endometrial tissue with endometrial glands surrounded by endometrial stroma especially in muscularis propria (Figure 2a,2b). The exact pathologic result was sigmoidal colon endometrioma.




Figure 1 : Gross appearance of the resection specimen. Lesions are mostly localised in submucosa and muscularis propria (white arrows). Note the small areas of mucosal erosion (star).

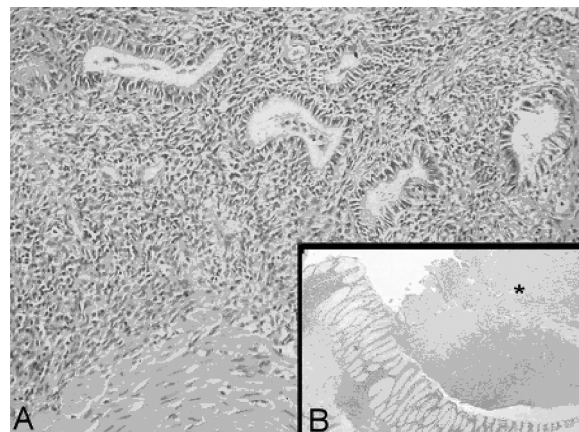


Figure 2a: Endometriosis. Endometrial glands surrounded by endometrial stroma. Muscle fibers of muscularis propria can be seen in the lower left corner (Hematoxylen &Eosin, x200).

Figure 2b: Low power view of the lesion. Mucosa appears normal. Focus of endometriosis can be seen between muscle layers of muscularis propria (Hematoxylen &Eosin, x40).

DISCUSSION

Endometriosis is a benign and often progressive disease in which tissue originating in the uterine lining spreads

locally by direct invasion or through the blood vessels to distant sites.

Although the exact frequency of intestinal endometriosis is difficult to know because of the lack of specific symptoms and reliable investigations, it has been estimated that implants to the bowel may occur in 3-37% of women affected by endometriosis (3*). The most common site of localization is sigmoid colon(4). The most common symptom of endometriosis is pain. Approximately a third of women who suffer from chronic pelvic pain have endometriosis and 40% of these women experience pain throughout the menstrual cycle(5). Although laparoscopic diagnosis of uterine endometriosis is quite specific, direct visualisation can be difficult or inaccurate in some circumstances, and it is not useful for diagnosing extra-abdominal disease. Extrapelvic involvement has been reported in nearly all organs of the abdominal cavity (Tablo I)(6). The frequency of segmental colectomy in bowel endometriosis ranges from 0,1% to 0,7%(7). In the present case except the adhesion between the left uterine tube and the sigmoid colon there were no endometriotic implants were visualized. The combination of two mechanisms can explain the occurrence of this case of colon endometrioma. For this case the most accepted mechanism is transportation theory suggests that visible endometrial cells reflux through the fallopian tubes during menstruation and implant and grow on the surrounding pelvic structures and peritoneum. In this case the menstrual reflux resulted with adhesions then with deep infiltration of endometriosis into fibromuscular tissue of the colon.

Table I: Distribution and incidence of endometriosis(6)

Location	Incidence
Appendix	1,0- 1,4%
Small intestine	0,2- 12,0%
Ureter	0,2- 0,6%
Lung/pleura	<0,5%
Umbilicus	0,8%
Cervix	2,5- 3,2%
Sigmoid colon	0,8- 12,1%
Omentum	0,6- 2,2%
Urinary tract	0,5- 1,6%
Abdominal wall	0,5- 4,5%
Inguinal canal	0,8%

Second, there is an association between the presence of endometriosis and an altered immun system which suggests that changes in cell-mediated immunity and humoral immunity and humoral immunity may contribute to the development of the disease, like increased the number of activated macrophages which produce substantially more fibronectin, a growth factor for fibroblasts, from such womens(8,9).

REFERENCES

1. Alan H. DeCherney, Lauren Nathan. Current Obstetric and Gynecologic Diagnosis and treatment. Ninth edition. 767-771.
2. Ulrich U, Richter O, Wardelmann E, Valter M, Schmutzler R, Sillem M, Possover M, Mallmann P. Endometriosis and malignoma. Zentralbl Gynakol. 2003 Jul-Aug; 125(7-8):239-42.
3. Bruno Deval, Arash Rafii, Michele Felce Dachez, Reza Keremash, Michel Levardon. Sigmoid endometriosis in a postmenopausal woman. Am J Obstet Gynecol. 2002;187: 1723-1725.
4. Caterino S, Ricca L, Cavallini M, Ciardi A, Camilli A, Ziparo V. Intestinal endometriosis. Three new cases and review of the literature. Ann Ital Chir. 2002 May-Jun; 73(3):329-9; discussion 329-330.
5. Brosens, I.A. (1990) Evolution of endometriotic lesions: is endometriosis a progressive disease? Preg Clin Biol Res 323, 151-156.
6. Moore, J.G. et al (1979) Urinary tract endometriosis: enigmas in diagnosis and management. Am J Obstet Gynecol 134, 162-172.
7. Collin G.R., Russel J.C. Endometriosis of the colon its diagnosis and management. Am Surg 1990; 56:275-279.
8. Halme J, Becker S, Haskill S. Altered maturation and function of peritoneal macrophages: possible role in pathogenesis of endometriosis. Am J Obstet Gynecol 1978;156:783-789.
9. Zeller JM, Henig I, Radwanska E, Dmowski WP. Enhancement of human monocyte and peritoneal macrophage chemiluminescence activities in women with endometriosis. Am J Reprod Immunol Microbiol 1987;13:78-82.